



www.kosmospublishers.com
contact@kosmospublishers.com
DOI: 10.37722/JNPABR.202401

Jesus Prayers Applied in Separation of Craniopagus Twins

András Csókay, MD, PhD^{1*}; István Hudák, MD, PhD¹; István Valálik, MD, PhD²; Attila Jósvai, MD¹; Bence Trencsényi, MD¹; Előd Égető MD¹; Gergely Csókay MD³; Bertalan Tóth, MS³

¹Department of Neurosurgery North-Pest Medical Centre, Military Hospital

²Department of Neurosurgery, St. John's Hospital, Budapest, Hungary

³Semmelweis University Budapest, Hungary

Received Date: December 21, 2023; **Accepted Date:** January 12, 2024; **Published Date:** January 28, 2024

***Corresponding author:** András Csókay, MD, PhD; Department of Neurosurgery North-Pest Central Hospital, Military Hospital, Str.44.Róbert K., Budapest H-1334, Hungary; Tel: +36 30 2227075; Email: csokaya@gmail.com

The published presentations describing the separation of this case of conjoined twins, did not describe the novel steps and techniques of the microsurgery part, which lasted 26 hours. Those presentations did not include the neurosurgical video either. The strategy of final separation was developed during day-by-day microsurgical practice on cadavers and did lead us to novel surgical solutions as the introduction of the application of hinge and distractors. One of the twins advanced to GOS 5 status during first five postoperative months, the other twin slowly advanced to GOS 3 status and remind at that functional level. The latter suffered the massive brain hemorrhage on postoperative day 33 which was leading to delayed rehabilitation and interfered with a potentially better outcome. The thorough analysis of the potential causative factors revealed the possible pathophysiological mechanism behind that complication. Two major factors have been identified; one of them is the traction related traumatic brain injury, which evolved during supine position. Another probable theory is the lack of a sufficient reconstruction of the posterior part of the skull (Fig.1) which caused a recurring tactile microtrauma of the brain due to the supine position. The hemorrhage may have been facilitated by the

fact that their coagulation tests were on the lower edge of normal parameters.

It was a mistake that this part of the surgery was not performed by neurosurgeons who designed it and practiced a lot on the fresh cadavers, on 3D models. Tactile microtraumas could be causative factor of haemorrhage. Sufficient cranioplasty was performed 3 months later.

It is impossible to say with certainty the cause of the hemorrhage, since there may have been other unknown causes, e.g. blood pressure spike. As a contributing factor, congestion of the veins is also possible.

We concluded that closer monitoring; a stricter management of the interdisciplinary teamwork and realizing the seriousness of the lack of sufficient structural support earlier could have prevented this unfortunate complication. In a similar case, we advise future professionals to use a halo ring postoperatively for posterior protection until a sufficient cranioplasty can safely be done.

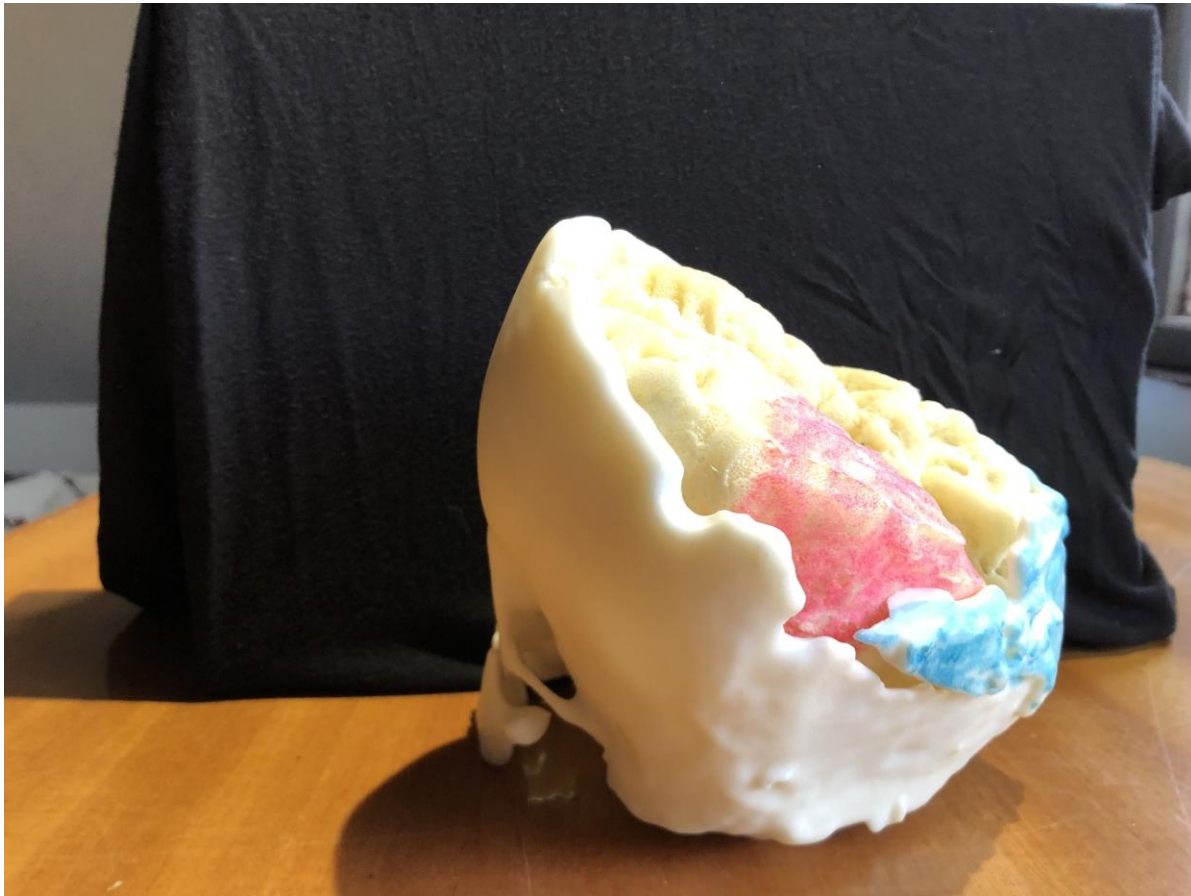


Figure 1: 3D model. Insufficient posterior bone protection (blue) with huge haemorrhage on dominant side (red)

Acknowledgement

The above mentioned scientific ideas as neurosurgical innovations (endovascular occlusion of common veins, application of hinge and distractor, continuous fresh cadaver excercises, special layered hemostasis) were born through the contemplative Jesus prayer “My Lord Jesus Christ, Son of the living God, have mercy on me, a sinner”

The personal experience of he of the last 22 years includes deep prayers that facilitate creative scientific ideas. It certifies there is no contradistinction between the faith and science as St II.John Paul Pope declared in his Encyclical Fides et Ratio (1999)

Specifically, we would like to express our gratitude first to:

Balázs SándorMuhari-Pap (painter) for the medical illustrations

János Szász (film director) leading the film footage from 4 camera positions.

Fr. Szabolcs Sajgó (SJ) and Fr. Péter Mustó (SJ) spiritual leaders of the hungarian neurosurgical team for giving specific moral support by teaching us the contemplative prayer of Jesus. The nuances and analysis of complications described in the paper were born during these prayers.

Thousands of spiritual and monetary donors

There are numerous hospitals, companies, and individuals from different countries that we wish to thank for their contributions to this work.

References

1. Khan ZH, Hamidi S, Miri SM. Craniopagus, Laleh and Ladan twins, sagittal sinus. Turk Neurosurg.2017; 17 :27-32.

Please follow the link to play the video: <https://kosmospublishers.com/wp-content/uploads/2024/01/Jesus-Prayers-Applied-in-Separation-of-Craniopagus-Twins.mp4>

Citation: Csókay A, Hudák I, Valálik I, Jósvai A, Trencsényi B, Égető E, Csókay G, Tóth B (2023) Jesus Prayers Applied in Separation of Craniopagus Twins. *Jr Neuro Psycho and Brain Res: JNPBR-184*