

Light and Electron Microscopic Study of Degeneration of Central Myelinated Axons in Human Traumatic Brain Injuries

Orlando J. Castejón*

Biological Research Institute, Faculty of Medicine. Zulia University and Institute of Clinical Neuroscience. Hogar Clinica San Rafael. Castejon Foundation. Maracaibo. Venezuela

***Corresponding author:** Orlando J. Castejón. Instituto de Investigaciones Biológicas “Drs. Orlando Castejón and Haydee Viloria de Castejón”. Facultad de Medicina. Universidad del Zulia. Apdo. 526. Maracaibo. Venezuela. Tel: +58 261 7414370; Email: ocastejo@gmail.com

Citation: Castejón OJ (2018) Light and Electron Microscopic Study of Degeneration of Central Myelinated Axons in Human Traumatic Brain Injuries. Jr surg opetech anesthesia: JSOPA-107.

Received Date: 9 August, 2018; **Accepted Date:** 28 August, 2018; **Published Date:** 6 September, 2018

Abstract:

In traumatic brain injuries of human edematous cerebral cortex degenerated myelinated axons in the gray matter underwent varicose fiber swelling, clear and dark types of axonal degeneration, myelin sheath vacuolization and distortion, formation of myelin ovoids, invagination and retraction of axoplasm, rupture of axolemma, cytoskeletal disruption featured by increased or reduced number of neurofilaments and fragmentation of microtubules, retraction of axoplasm, enlargement of periaxonal space, and partial or total disappearance of axoplasmic organelles. Phagocytosis of degenerated myelinated axons by reactive oligodendrocytes, astrocytes, microglial cells, and non-nervous professional phagocytes is observed in mild and severe traumatic brain edema. Some biochemical events are postulated underlying myelinated axonal degeneration.

Keywords: Axonal Degeneration; Electron Microscopy; Light Microscopy; Neuroglial Reaction

Introduction

Since the advent of transmission electron microscope numerous ultrastructural studies of Wallerian degeneration of peripheral nerves have been reported by many Authors. In the central nervous system such earlier and pioneering studies are also numerous [1-16]. These studies have characterized the basic electron microscopic features of central axonal degeneration, and demonstrated that the submicroscopic pathology of axonal disease can

be quite diverse even following the same mechanism of injury. In order to study its basic pathogenetic mechanism, degeneration of central myelinated axons has been experimentally induced in some animals, such as rats and guinea pigs. In this context, Lampert (1968) [13] and Hirano (1972) [17] have thoroughly revised the alteration of subcellular structures of central myelinated axons in numerous experimentally induced pathologic conditions, and in samples of human material.

In the edematous central nervous system more attention was given primarily to the study of myelinated axons of the white matter [6, 21, 22]. Disappearance of filaments and microtubules was

reported by Darrel (1973) in Wallerian degeneration of the corticospinal tract. Schlaepfer (1974) [23] earlier related the granular disintegration of microtubules and neurofilaments with the influx of extracellular calcium ion to the axoplasm (hypothesis of Wallerian degeneration by influx of calcium). Decomposition of neurofilaments and microtubules was later reported by Tucek *et al.* (1978) [24] as induced by ischemia. Hardman (1979) elegantly reviewed the features of primary and secondary traumatic lesions in the CNS, and the axonal reactive swelling. Genarely *et al.* (1985) earlier described the diffuse axonal injury in traumatic coma in primates. Castejón (1985) reported the axonal degeneration in myelinated axons of human edematous cerebral cortex associated to severe human traumatic brain injuries. Cheng and Povlishock (1988) found reactive axonal changes after traumatic brain injury of visual system. Erb and Povlishock (1988) [25] reported organelle accumulation and focal axolemmal distention without frank disruption in severe traumatic brain injury. Blumbergs *et al.* (1989) [26] demonstrated diffuse axonal injury in patients with head trauma. Shigemory *et al.* (1992) [27] found coexisting diffuse axonal injury and outcome of severe human head injury. Yamaki *et al.* (1992) [28] described remarkable destruction of cytoskeletal structure in human who died shortly after impact. Gennarelli (1993) [29] described traumatic defect of axonal membrane that causes the excessive accumulation of calcium ions within the intracellular compartment. Povlishock (1992 a,b, 1993) [30], Povlishock and Kontos (1992) [31], Christman *et al.* (1992) [32], Pettus *et al.* (1994) [33], and Povlishock *et al.* (1999) [34], using animal models of traumatic brain injury, complemented by *post mortem* human analyses, reported neurofilament misalignment, loss of focal side arms, compaction, and neurofilament disassembly. Cytoskeletal derangement following central nervous system injury also was later described by Hayes *et al.* (1995) [35]. Pierce *et al.* (1996) [36] demonstrated intra-axonal accumulation of amyloid precursor proteins and beta amyloid peptide after lateral fluid percussion injury. Posmantur *et al.* (1996 a,b) [37,38] reported cytoskeletal derangements of cortical neuronal, and diminished microtubule-associated protein 2 (MAP2) immunoreactivity following cortical impact in brain injury processes three hours after traumatic brain injury in rats. Cytoskeletal alterations following central nervous system injury also was reported later by Saatman *et al.* (1998) [39]. Many of these investigations provided important insight into mechanisms possibly

mediating loss of cytoskeletal proteins including disturbance in calcium homeostasis, and activation of calcium-dependent proteolytic enzymes. The perturbations of axolemma and the cytoskeletal alteration were associated with impairment of axoplasmic transport [40-43]. These findings suggested that a direct mechanical effect on the axonal cytoskeleton is a pivotal event in the initiating pathogenesis of axonal injury [44]. Bramlett *et al.* (1997) [45] demonstrated the presence of beta amyloid precursor protein in axons after traumatic brain injury. Kampfl *et al.* (1998) and Wang *et al.* (1998) [46] described diffuse axonal injury after closed head injury as the major form of primary brain injury in posttraumatic persistent vegetative state. Bidman *et al.* (1998) found alterations and changes in cytoskeletal proteins and proteoglycans after focal cortical ischemia. Wang and Hou (2000) [47] also reported neurofilament misalignment in a model of diffuse axonal injury and focal brain injury in rats. Nashmi and Fehlings (2001) [48] found thin myelin sheath in axons of rat thoracic spinal cord after chronic compressive injury. Adelson *et al.* (2001) described significant axonal damage after diffuse traumatic brain injuries. Raghupathi and Margulies (2002) [49] reported accumulation of neurofilaments after closed head injury in neonatal pigs. Axonal injury in children after motor vehicle crashes was reported by Gorrie *et al.* (2002) [50]. Cheng *et al.* (2003) found disrupted neurofilaments after controlled cortical impact. Huh *et al.* (2003) described transient loss of microtubule-associated protein 2 immunoreactivity after moderate brain injury in mice. Maxwell *et al.* (2003) [51] reported a differential response between microtubules and neurofilaments in animal models of traumatic axonal injury. Saatman *et al.* (2003) [52] demonstrated disruption of retrograde axonal transport and progressive accumulation and dephosphorylation of neurofilament protein in swollen and disconnected axons. Hamberger *et al.* (2003) [53] reported reduced heavy phosphorylated neurofilament subunit in the axons after rotational trauma. Smith *et al.* (2003) [54] found amyloid beta accumulation in axons after traumatic brain injury in humans. Hoshino *et al.* (2003) [55] used multiple immunostaining to detect traumatic axonal injury in the rat fluid-percussion brain injury model. Khan (2004) described myelin sheath splitting, intramyelinic and periaxonal edema and occurrence of amorphous and electron dense material in the degenerated rabbit optic nerve. Stone *et al.* (2004) [56] demonstrated impaired axonal transport and altered axolemmal permeability in

damage axons following traumatic brain injury. Hall et al. (2004) [57] described peroxynitrite-mediated protein nitration and lipid peroxidation in a mouse model of traumatic brain injury. Khan (2004) [58] reported splitting of myelin, intramyelinic and periaxonal edema and occurrence of amorphous and electron dense material in rabbit degenerated optic nerve. Castejón and Acurero (2004) described axolemmal and cytoskeletal derangement in patients with severe human traumatic brain injuries and loss of consciousness. Rodriguez-Paez et al. (2005) [59] found reduction in the number of myelinated fibers following traumatic brain injury in the rat. Stys (2005) [60] reviewed the biochemical and molecular cascades of axonal damage. Chung et al (2005) [61] demonstrated that mild axonal stretch injury in vitro induces a progressive series of neurofilament alterations ultimately leading to delayed axotomy in mildly and strong injured axons. Marmorou et al. (2005) [62], using immunohistochemical methods, made a quantitative analysis of the relationship between intra-axonal neurofilament compaction and impaired axonal transport following diffuse traumatic brain injury in rats. Reeves et al. (2005) [63] demonstrated the differential vulnerability of myelinated and unmyelinated axons of corpus callosum following traumatic brain injury in rats. Gallyas et al. (2006) [64] described the degenerative morphological changes of traumatic compacted axons in rats. Kelley et al. (2006) [65] identified impaired axonal transport, deposit of amyloid precursor protein, and axolemmal alteration after fluid percussion brain injury in rats. Petzold et al. (2005, 2006) [66,67] studied human axonal degeneration in subarachnoid hemorrhage, and found an increase in the neurofilament heavy chain.

In the present review we describe by means of light and electron microscopy the degeneration of myelinated axons in the gray matter of edematous human cerebral cortex in severe human traumatic brain injuries, and the reactivity of periaxonal neuroglial cells, using human cortical biopsies immediately processed for transmission electron microscopy.

1. Light Microscopy of Degenerated Myelinated Axons

Semithin plastic section examined with the light microscope showed the undulated and beaded shaped of degenerated longitudinally sectioned myelinated axons (**Figure1**).

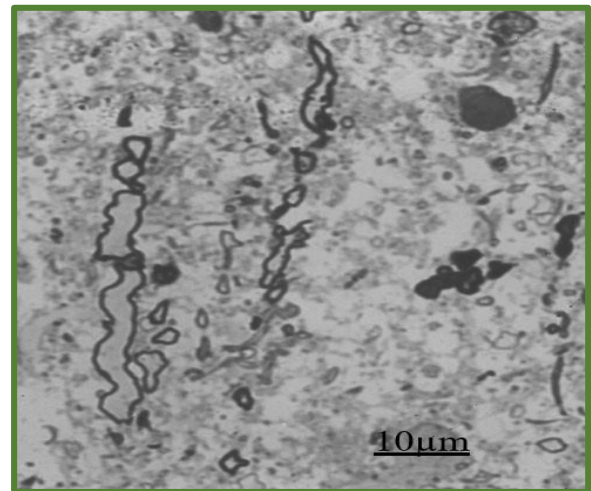


Figure 1: Brain trauma. Subdural hematoma. Photomicrograph of semithin plastic section of degenerated myelinated axons in a severely swollen brain parenchyma exhibiting status spongiosus.

Electron microscopy of perivascular region shows the cross section of degenerated myelinated axons surrounded by large extracellular spaces occupied by the extravasated hemogenous edema fluid originated from the traumatic vasogenic edema (**Figure 2**).

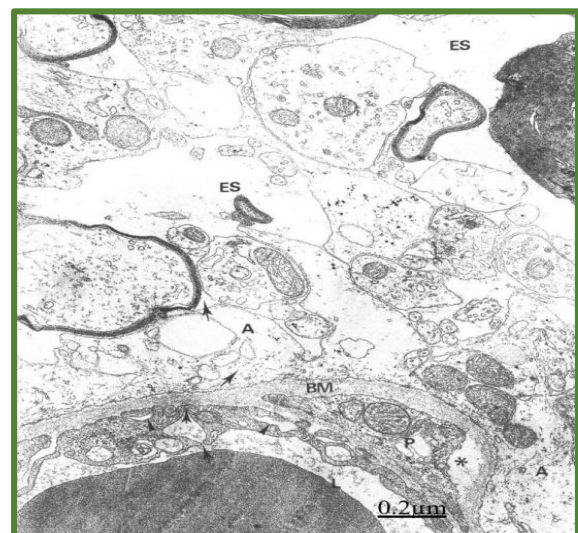

Figure 2: Brain trauma. Subdural hematoma. Low magnification electron micrograph showing the cross sections of degenerated myelinated axons surrounded by enlarged extracellular space (ES). The neighboring brain capillary displays the

transendothelial vacuolar transport, swollen basement membrane (BM), edematous pericite (P). The short arrows indicate the vasogenic edema induced by the hematogenous edema fluid; Note the swollen astrocyte cytoplas (A).

2. Ultra Structural Pathology of Myelin Sheath

A remarkable enlargement of the myelin periods was noted according to the severity of brain edema, which induces progressive widening of the intraperiod space and splitting of intraperiodic lines, resulting in formation of small and large vacuoles with a clear content, due to overhydration of myelin sheath multilamellar arrangement (**Figure 3**).

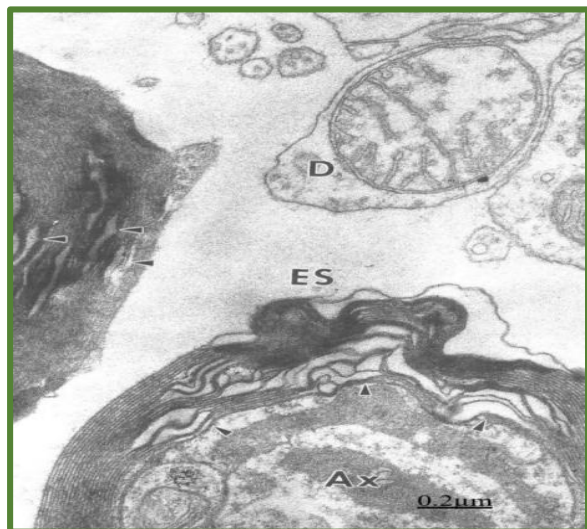


Figure 3: Brain trauma- Vacuolated myelin sheath (arrowheads) surrounded by lacunar spaces of extracellular space (ES). The axoplasm (Ax) shows the dark degenerated mitochondria. A degenerated dendritic profile (D) also is distinguished.

The outer myelin bulbs of degenerated myelinated axon permeate the neighboring neuropile. The axonal cytoskeleton appears fragmented (**Figure 4**).

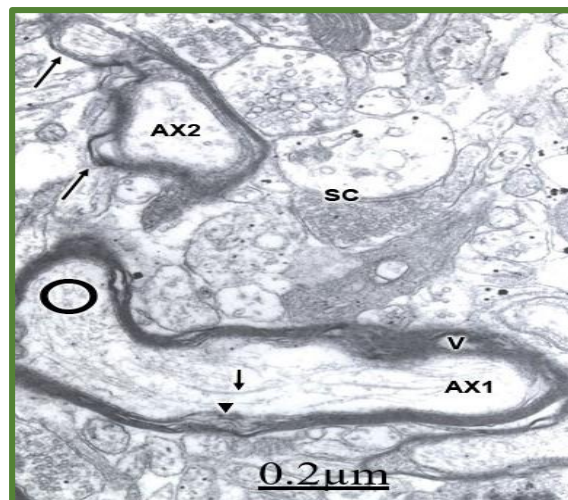


Figure 4: Brain trauma and subdural hematoma. Left parietal cortex. Longitudinal section of a degenerated myelinated axon (AX1) showing vacuolization (V) of myelin sheath. The arrowhead labels the separation of myelin lamellae. The clear axoplasm exhibits fragmented microtubules (short arrows) and neurofilaments (circles). The cross section of another axon (AX2) shows the formation of outer myelin ovoids (long arrows) insinuating among the nerve cell processes of neighboring neuropile. Note the presence of degenerated axodendritic synaptic contact (SC), and the enlargement of extracellular space.

The enlargement of interlamellar space resembles to that described in peripheral nerves exposed to hypotonic solutions, metachromatic leukodystrophy, culture cells after X-irradiation, allergic encephalomyelitis, and in edema produced by implantation of silver nitrate [13]. According to Lampert, the water molecules would bind to lipoproteic layers of the intraperiodic line or minor dense line, splitting them apart.

Myelin Sheath Vacuolization

Myelinated axons with a secondary sheath of vacuolized redundant myelin are also found. Vacuolization of myelin sheath is a widely reported finding in earlier light and electron microscopic studies of edematous gray matter (Gruner, 1967; Zulch, 1967; Hirano et al., 1969) [68-70]. In experimental cerebral edema, the formation of intramyelinic vacuoles has been studied by numerous investigators. Bakay and Lee (1965) [71] described division and vacuolization of the myelin sheath

induced by triethyltin compounds in rat white matter. These Authors did not observe changes of myelin sheath in the gray matter. Lampert and Schochet (1968) [21] reported myelin vacuolization without apparent damage to the glial cells and few degenerative changes in the myelinated axons of duck white matter after isoniazide administration. They proposed that vacuole formation could be related with the inhibition of ATPase system by the isoniazide. Lampert (1968) [13] referred to the presence of myelinated vacuoles in edema by cryptococcal polysaccharide implantation, and in the spongy degeneration of the brain. Blakemore *et al.* (1972) [73] found myelin vacuolization, hypertrophic astrocytes and degenerated oligodendrocytes in dog cerebral edema induced by isoniazide. Khan (2004) [58] showed splitting of myelin sheath, intramyelinic and periaxonal space and presence of electron dense material in degenerated rabbit optic nerve.

Hypothesis on the Weakening of Van Der Waals Forces in the Myelinolytic Effect of Brain Edema

The myelin intermolecular stability is of fundamental importance in the preservation of physical integrity of myelin layer. The physico-chemical factors which promote myelin stability should be considered before discussing the changes that occur during myelin hydration, vacuolization, distortion and granular disintegration in brain edema. The electron microscopic, polarization and X-ray diffraction studies indicate that the myelin lamellar structure is essentially composed of circumferentially arranged protein layers and layers of radially directed lipid molecules. The molecular stability of myelin depends upon the bonds between these layers and on the intermolecular bonds within them. The stabilization of these layers in a radial direction should be due principally to columbic or ionic association complexes between phosphoryl groups or basic phospholipid groups, and the corresponding cationic or anionic groups in the protein layer. The myelin is circumferentially or longitudinally stabilized by the protein layer and by the van der Waals forces between the fatty acid chains and the cholesterol molecules in the lipid layers [74]. The water molecules have a dipolar moment and may affect the distribution of the charges between these closely associated molecules, establishing a distribution of charges subject to fluctuations. This induced effect originates separation of the charges,

which is lesser than that found between the lipid molecules, giving, as a result, lesser interaction energy and in consequence weaker chemical bonds [75]. The increase of the water content of the cerebral tissue, as occurs in brain edema, should weaken the van der Waals attraction forces existing between the lipid molecules and should also weaken the saline unions between the phospholipid and protein molecules, which should produce dilation of the interlamellar spaces, vacuolization and physical distortion of the myelin sheath. Finean and Woolf (1962) [76] earlier emphasized the role of physical agents in the weakening of adhesion forces existent between myelin lamellae as the cause of myelin distortion. In our study on human cortical biopsies, the physical forces would be represented fundamentally by the physical intensity of traumatic agent and the expansive growth of the hematoma or hygroma, and also by the presence of edema fluid infiltrating the neuropil. The distortion of the myelin sheath appears as consequence of the formation of large intramyelinic vacuoles. Severe distortion of the myelin sheath associated to widely dilated neighboring extracellular spaces suggests that the edema fluid present in these spaces would filter through the outermost myelin sheath lamella. This observation clarifies a fundamental question about edema pathology early formulated by Zulch (1967) [69], on the probable role of unstained edema fluid in myelin swelling.

Disruption of Cytoskeletal Structures

Increased amount of actin-like-filaments and a decrease of microtubules are observed in some patients with severe traumatic brain injuries (Figure 5).

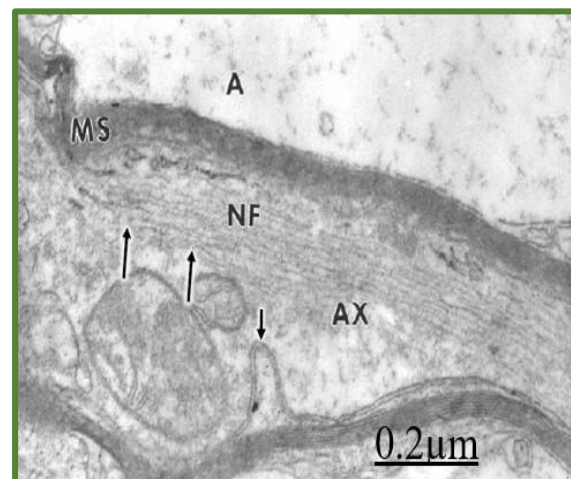


Figure 5: Contusion and fracture of frontal region. Left frontal cortex. Longitudinally sectioned myelinated axon (AX) showing a bundle of parallel arranged neurofilaments (NF). Some of them appear fragmented (long arrows). Note the absence of microtubules. The axolemma shows an invagination (short arrow). Note the damaged myelin sheath (MS) and the neighboring swollen and glycogen-depleted astrocyte (A).

Castejón and Acurero (2004) demonstrated, by means of transmission electron microscopy, granular disintegration of microtubules, misaligned and fragmented neurofilaments, and disrupted axolemma. Marmorou et al. (2005) [62] found that neurofilament compaction is not associated with impaired axonal transport in diffuse axonal injury. This differential response was also described by Jafari et al. (1998) and Maxwell et al. (2003) [51] in guinea pig optic nerve after traumatic axonal injury, by Sun et al. (2002) in a guinea pig model of diffuse axonal injury, and by Okonkwo et al. (1998). The differential response between microtubules and neurofilaments is presumably due to the effect of vasogenic cerebral edema, which induces microtubular disassembly. Apparently due to the intensity of traumatic agents, the constitutive protofibrils of microtubules become separated, thus forming filaments (Castejón, 1985). Decomposition of neurofilaments and microtubules was earlier reported by Tucek *et al.* (1978) [24] as induced by ischemia. Lately, Yamaki *et al.* (1992) [28] described remarkable destruction of cytoskeletal structure in human who died shortly after impact. Povlishock (1992, 1993) [30,77], Christman *et al.* (1992) [32], Pettus *et al.* (1994) [33], using animal models of traumatic brain injury, complemented by *post mortem* human analyses, reported neurofilament misalignment, loss of focal side arms, compaction and neurofilament disassembly. Cytoskeletal arrangement following central nervous system injury also was reported later by Hayes *et al.* (1995) [35]. Pettus and Povlishock (1996) [78] described alterations in axolemmal permeability to horseradish peroxidase linked with distinct cytoskeletal changes. Posmantur *et al.* (1996a, b) [37,38], and Saatman *et al.* (1998) [39] demonstrated alterations in cytoskeletal proteins, such as microtubule associated protein-2 (MAP2) following brain injury. High density of neurofilaments has been also described in sprouting axons following brain injury (King et al., 2001) [79]. Stone et al. (2001) [80] reported neurofilament compaction, progressive accumulation

of cell organelles, and increased axonal swelling. Chung et al. (2005) [61] found neurofilament compaction, and mildly injured axons with increased neurofilament immunoreactivity and ring-like neurofilament immunoreactivity in a new model of transient axonal stretch injury. Stone et al. (2004) [56], using markers of axolemmal integrity and marker of impaired axoplasmic transport, confirmed that axolemmal disruption and impaired axoplasmic transport occur as distinct non-related events early in the pathogenesis of traumatic axonal injury.

The increased amount of neurofilaments seems to be an unspecific axoplasmic reaction which has been found in a great variety of pathological conditions. It has been earlier observed in reactive axons after the administration of B-B' iminodipropionitrile and aluminium phosphate and in acrylamide intoxication and chronic experimental cyanide intoxication [81]. Proliferation of filaments and loss of microtubules have also been observed after the administration of colchicine, vinblastine and vincristine [17]. Malbouissou et al. (1985) reported loss of microtubules in degenerated rat small nerve fibers. Raghupathi and Margulies (2002) [49] demonstrated accumulation of neurofilament protein in swollen axons after close head injury of neonatal pigs. Huh et al. (2003) [82] reported transient loss of microtubule associated protein 2 (MAP2) after moderate brain injury in mice. Saatman et al. (2003) [52] showed progressive accumulation and dephosphorylation of neurofilament protein in swollen and traumatically disconnected axons. Gallyas et al. (2006) [64] demonstrated neurofilament compaction in rat calvaria after head injury. Granular disintegration of filaments and fragmentation and disappearance of microtubules also is observed in severe and complicated traumatic head injuries (Figures 6&7).

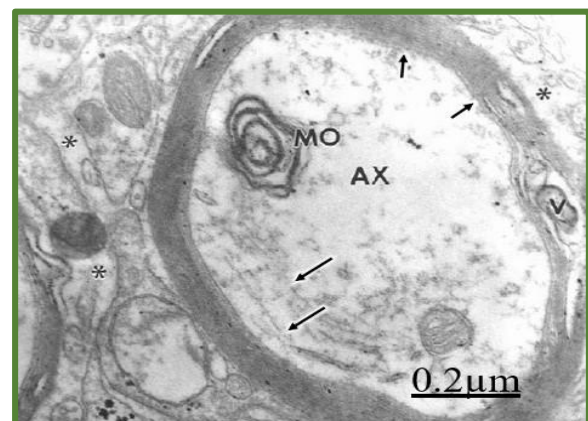


Figure 6: Brain trauma. Left fronto-parieto-occipital subdural hematoma. Left parietal cortex. Cross sectioned myelinated axon showing edematous and electron lucent axoplasmic matrix (AX) with scarce and fragmented neurofilaments (long arrows), and fragmented axolemma (short arrows). Microtubules are absent. An axoplasmic myelin ovoid (MO) also is seen. Note the enlarged extracellular space (asterisks) in the neighboring neuropil.

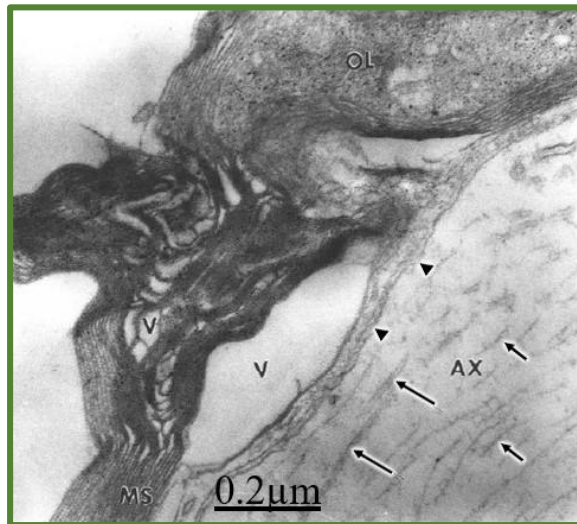


Figure 7: Brain trauma and right parieto-temporal subdural hematoma. Right temporal cortex. Electron micrograph showing the disrupted microtubules (long arrows) and neurofilaments (short arrows), and the disrupted axolemmal membrane (arrowheads). Myelin sheath distortion and vacuolization (V) also is noted. Interlamellar hypertrophic oligodendroglial cytoplasm (OL) is observed invading the intraperiod space, and separating the interlamellar arrangement of myelin sheath. X 90.000.

Swollen axons with axoplasm devoid of cytoskeletal component were described by Dietrich et al. (1996) after fluid percussion brain injury in rats. Stys and Jiang (2002) reported calpain-dependent neurofilament breakdown in anoxic-ischemic rat central axons. This finding has also been earlier reported in degenerated axons of spinal cord after sectioning of the dorsal ascending tract [81], and in experimental allergic encephalomyelitis [83]. Schlaepfer (1974) [23] has related the granular disintegration of microtubules and neurofilaments with the influx of extracellular calcium ion to the axoplasm (hypothesis of Wallerian degeneration by

influx of calcium). In advanced axonal degeneration disappearance of filaments and microtubules is observed in a similar way to that reported by Darrel (1973) [18] in Wallerian degeneration of the corticospinal tract. Backstrom and Collins (1987) [84] found that excess material in rat axonal swelling after 2, 5 hexanediol treatment was due to neurofilament proteins and not tubulin proteins. Hamberger et al. (2003) [53] have shown a decreased of phosphorylated heavy subunit of neurofilaments after rotational head trauma.

The Clear Type of Axoplasmic Degeneration

As illustrated in Figs.5 and 6, the swollen axoplasm shows a clear or matrix, increased or reduced number of neurofilaments, partial loss of organelles, deep invaginations and fragmentation of axolemma, axolemmal blebs, protein aggregation characterized by a flocculent precipitate or clumpy osmiophilic axoplasmic material dispersed throughout the axoplasm, and disruption of microtubules. The watery appearance of clear myelinated axons is due to severe axonal swelling and degeneration. Moderate or marked dilation of the smooth endoplasmic reticulum is observed, which suggests intracellular edema with increased circulation of water and electrolytes. Similar observations have been reported in cyanide poisoning, hypoglycemia, hypoxia, experimental glaucoma, and after sectioning of peripheral or central axons [17].

Axolemmal alterations in traumatic axonal injury was earlier reported by Castejón (1985), and lately by Gennarelli et al. (1985,1989) [85], Povlishock and Christman, (1995,1996) [40,41], Povlishock and Pettus, (1996), Maxwell (1996), Singleton et al. (2002) [40], and more recently by Stone et al. (2004) [56] and Kelley et al. (2006) [65]. Axonal swelling and organelle loss seem to be related with the metabolic suppression of mitochondrial oxidative energy. According to Stys (2005) [61] when energy supply is limited ion gradients breakdown, unleashing a variety of aberrant cascade, ultimately leading to Ca^{++} overload. During Na pump dysfunction, Na^{+} can enter axons through non-inactivating Na^{+} channels, promoting axonal Na^{+} overload, and depolarization by allowing K^{+} egress. This will gate voltage sensitive Ca^{++} channels and stimulate reverse Na^{+} - Ca^{++} exchange, leading to further entry of Ca^{++} . Energy failure will also

promote Ca^{++} release from intracellular stores. Neurotransmitters such as glutamate can be released by reverse operation of Na^{+} -dependent transporter, in turn activating a variety of ionotropic and metabotropic receptors, further exacerbating overload of cellular Ca^{++} . Together, this Ca^{++} overload will inappropriately stimulate a variety of Ca^{++} dependent enzymes (e.g. calpains, phospholipases), leading to structural and functional axonal injury. Accumulation of Ca^{++} in the brain following head trauma was earlier reported by Shapira et al (1989) [86]. In addition to the depressed energy metabolism, cerebral oxidative stress is related with the damage of cytoskeletal structures, myelin sheath multilamellar arrangement and axolemmal fragmentation. Peroxidative stress has been implicated in mechanism leading to neuronal cell injury (Paschen et al., 2001; Boldyrev et al., 2000; Evans, 1993; Choi, 1993) [87]. One source of free radicals in ischemic cells is arachidonic acid released by membrane phospholipids under the action of Ca^{2+} -activated phospholipase A_2 (Keuhl and Egan, 1980). Several oxygen radical species besides superoxide radicals are produced following hypoxia. Superoxide radicals have been shown to change phospholipid and protein structure. Hydroxyl radicals are the most reactive and are known to initiate lipid peroxidation and protein oxidation and nitration [57,88-90]. Peroxidation of polyunsaturated fatty acids damages cell membranes and disrupts transmembrane ionic gradients. The products of lipid peroxidation are aldehydes, hydrocarbon gases, and other metabolites that can cause cytotoxic and vasogenic edema, as observed in our electron micrographs. Iron derived from hemoglobin of intraparenchymatous hemorrhages can serve as a catalyst for free radical mediated oxidation leading to enhanced secondary tissue damage [90]. Practico et al. (2002) [91] using a marker of lipid peroxidation showed local and systemic increase in lipid peroxidation after moderate experimental brain injury. Tavazzi et al. (2005) have demonstrated, by means of high-performance liquid chromatography on whole brain tissue extracts, the close relationship between the degree of oxidative stress and the severity of brain insult.

The Dark Type of Axoplasmic Degeneration

Some dark myelinated axons underwent the so-called electron dense or black type of axonal degeneration (Figure 8).

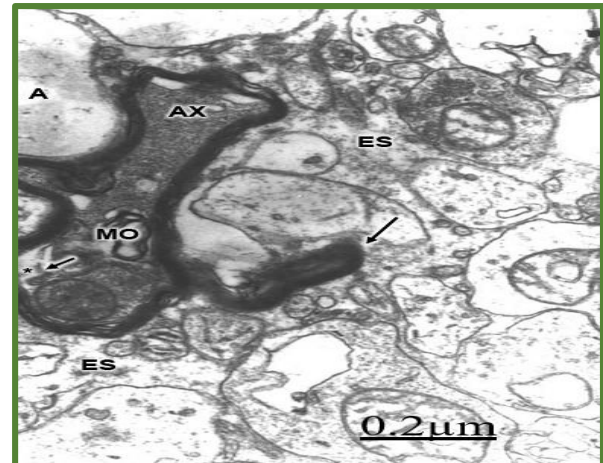


Figure 8: Brain trauma and associated subdural hematoma. Right parietalcortex. Dark type of axonal degeneration. Note the high electron density of axoplasmic matrix (AX) and the redundant layer of myelin sheath permeating the neuropil (long arrow). Cytoskeletal structures are not visible. Inner myelin ovoids (MO) are also distinguished. The axoplasmic retraction (short arrow) induces enlargement of periaxonal space (asterisk). The extracellular space (ES) appears notably enlarged, and containing proteinaceous edema fluid.

The myelinated axons show tortuous or beaded aspect with successive constrictions and dilations classically described by light microscopic studies. The accentuated tortuosity caused the formation of protrusions of myelin bulbs toward the neighboring neuropil. In some areas, the myelin sheath exhibits variable degrees of vacuolar and vesicular degeneration. Swollen and ballooned axons were also described by Cervos- Navarro and Lafuente (1991) [92] around the contusion zone and far from it.

The axoplasmic darkening was earlier reported by Cajal (1928) [93] and subsequently by Lampert and Cressman (1966) [93], Laatsch and Cowan [94], Gray and Hamlyn (1972) [16]. As suggested by Dunkerley and Duncan (1969) [15], the increased density of degenerating axoplasm may be accounted for by shrinkage due to loss of water by contraction of axoplasm or by chemical changes that result in greater uptake of osmium and the metallic stains used in the preparative techniques for electron microscopy. However, what is really intriguing is the observation of clear degenerated axons in the neighboring neuropil. These observations suggest that the central Wallerian degeneration is not a chronologically

uniform process, and that different axons are undergoing early and late degeneration, or presumably is due to different axoplasmic chemical composition. In favor of this latter idea is the observation of the dark type of axonal degeneration in indolamine axons induced by 5,6 dihydroxytryptamine (Baumgarten *et ai*, 1972) [95]. Glutaraldehyde used as the primary fixative in conventional transmission electron microscopy is a very efficient protein-stabilizer by means of cross-linking [96], and the darkening of axoplasm is apparently due to the reaction of glutaraldehyde with protein aggregations formed during the degenerative process.

Formation of Myelin Ovoids

As illustrated in Figures. 3 and 5, fragmentation of myelinated axons and formation of outer and inner myelin ovoids are observed. Often the outermost lamellae became detached and burst into the dilated extracellular spaces. Between the large vacuoles and the myelin ovoids, abundant hypertrophic oligodendroglial cytoplasm with numerous electron dense granulations is seen. The periaxonal spaces appeared invaded by the hypertrophic oligodendrocytes. The inner and outer myelin ovoids show retracted axoplasm containing membrane remnants, and in some their axoplasmic content was clear without evidence of axoplasm. Their myelin sheaths are collapsed or vacuolized, and a few cases showed common lamellae with the parent axons. Ng et al. (1994) described myelin globoids as a form of myelin damage secondary to axonal disruption.

The Alterations of Periaxonal Space

The axoplasmic retraction induce enlargement of the periaxonal space located between the axolemma and the inner most myelin lamella. The periaxonal space shows moderate dilation in early axonal degeneration due to a slight retraction of the axon, and is observed apparently normal in those myelinated areas with well preserved myelin multilamellar arrangement. Marked enlargement of this space was observed in very severe edema and advanced grades of degeneration (**Figure 9**).

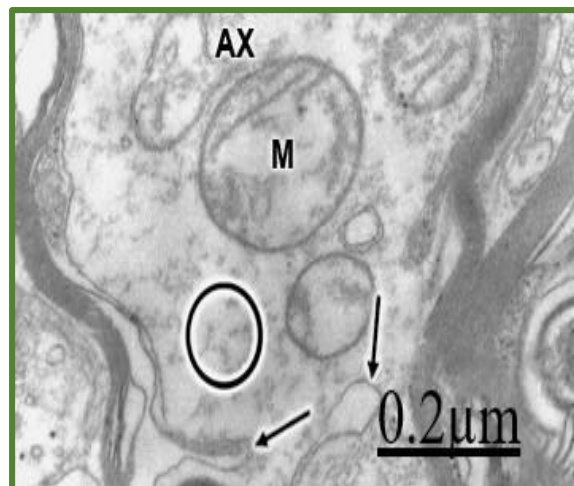


Figure 9: Brain trauma. Subdura hematoma. Left parietal cortex. Severely degenerated axon (AX) showing deep invaginations of axolemmal membrane (arrows) and enlargement of periaxonal space. The circle shows the granular disintegration of neurofilaments. Swollen mitochondria (M) also are seen.

The enlargement and vacuolization of periaxonal space could be produced by filtration of edematous fluid from the extracellular space through the myelin sheath transverse bands. These bands have been proposed by Hirano and Dembitzer (1969) [70] as a way of access from the extracellular space to the periaxonal space. Alterations of the periaxonal space have also been observed in lead neuropathy [97], and in other types of cerebral edema (Lampert, 1968) [13].

In advanced degeneration the axoplasm is replaced by a flocculent and electron dense material (**Figure 10**) resulting from disintegration of cytoskeletal structures and cell organelles. Protein and degenerated organelle accumulation in traumatic brain injury also results from interruption of axonal transport.

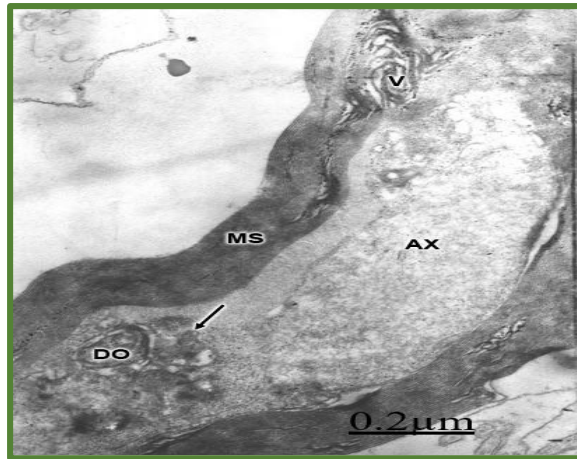


Figure 10: Brain trauma complicated with a subdural hematoma. Left parietal cortex. Irregularly shaped myelinated axon with advanced degeneration showing myelin sheath (MS) disruption and vacuolization (V), a granular material deposited in the axoplasm (AX), protein accumulation (arrow), and degenerated organelles (DO) evincing interruption of axoplasmic transport. X 36.000.

The following axoplasmic proteins have been characterized by Smith et al. (2003) [98], such as: beta-amyloid precursor protein and its proteolytic products, amyloid beta (abeta) peptides, neurofilament proteins, and synuclein proteins.

The Positive Marchi Reaction of Degenerated Myelin Sheath

As illustrated in Fig. 10 a highly electron dense granular deposit is observed in the degenerated myelin sheath, which seems to correspond to a selective precipitate of osmium tetroxide. Following the initial phase of physical myelin disintegration, a chemical degradation of the myelin lipids is produced [74]. Presumably at the electron microscope level this granular deposit is a positive Marchi reaction [99], in which degraded phospholipids are selectively stained. These alterations closely resemble those described by Schlaepfer (1969) [100] in experimental lead neuropathy, especially the granular disintegration of axoplasm and the disruption and partial myelin collapse.

Myelin Sheath-Oligodendroglial Relationship in Human Brain Edema

The examination of scanning transmission semithin plastic sections of severe dematous regions shows dense oligodendrocyte surrounding the degenerated myelinated axons (Figure 11).

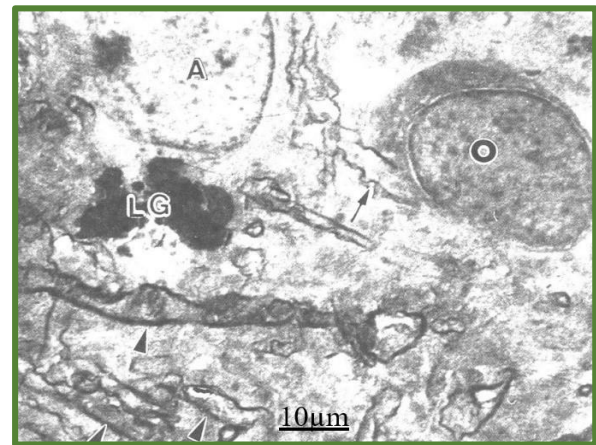


Figure 11: Brain trauma. Subdural hematoma. Scanning transmission electron micrograph of a semithin plastic section showing a swollen dense oligodendrocyte (O) and a clear edematous astrocyte (A) with large lipofuscin granule (LG) surrounding a degenerated myelinated axon (arrowhead).

At the electron microscopy level the notably swollen oligodendrocyte appear in close topographic relationship to the degenerated myelinated axon (Figure 12).

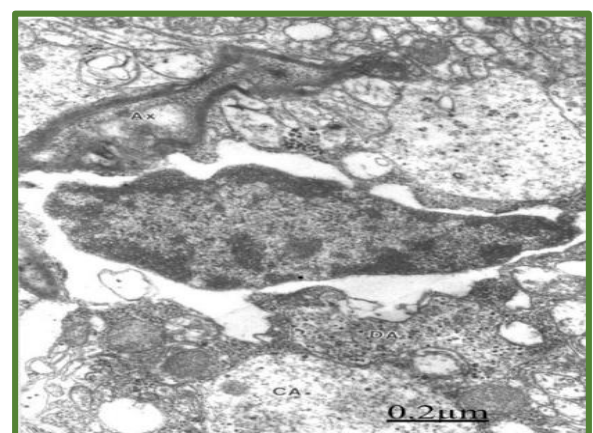


Figure 12: Brain trauma. Subdural hematoma. Notably swollen hydronic oligodendrocyte associated to degenerated axon (AX), and surrounded by clear swollen astrocyte cytoplasm (CA).

Injury to the central nervous system results in oligodendrocyte cell death and progressive demyelination. Demyelinated axons undergo considerable physiological changes and molecular reorganizations that collectively result in axonal dysfunction, degeneration and loss of sensory and motor functions [101]. According to Flygt et al. (2013) [102], traumatic brain injury induces oligodendrocyte apoptosis and widespread myelin loss,

Phagocytosis and Digestion of Degenerated Myelinated Axons

In advanced axonal degeneration observed after a long evolution time of brain injury, partial or total disappearance of axoplasmic matrix is seen, which appears occupied by large vacuolar spaces. Reactive oligodendrocytes invade the myelin sheath and phagocyte the axoplasm by means of large pseudopodic expansions, leaving a huge vacuolar space in the site previously occupied by the axoplasm. These spaces are limited by the innermost myelin lamellae and the hypertrophic oligodendroglial cytoplasm. Similar behavior has been earlier reported in Schwann cell by Singer and Steinberg (1972) [7] in transected and colchicine-poisoned nerves.

Phagocytosis by Microglial Cell

Dark microglial cells appear phagocytosing the degenerated myelinated axons (Figure 13).

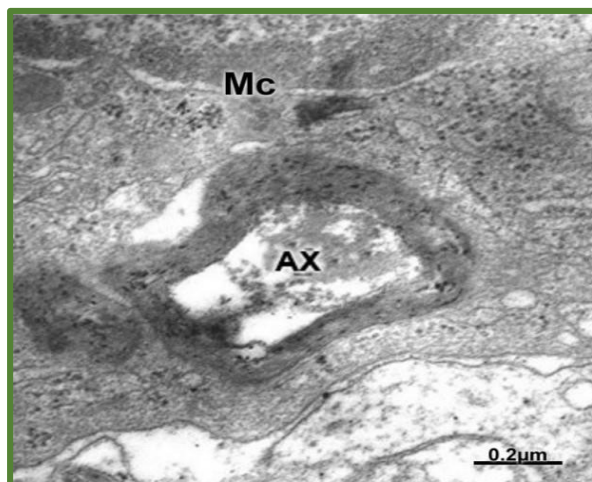


Fig.13. Brain trauma. Subdural hematoma. Left frontal cortex. Electron micrograph showing a dark

phagocytic microglial cell (Mc) with an engulfed degenerated myelinated axon (AX).

Hill et al. (2018) [103] recently reported myelin debris accumulation within microglia in myelin degeneration during aging process. Zindler and Zipp (2010) [104] postulate that activated microglia and peripherally derived macrophages are shifted towards a strongly pro-inflammatory phenotype and produce the proinflammatory cytokines TNF- α and interleukin (IL)-1 β , as well as potentially neurotoxic substances including nitric oxide, oxygen radicals and proteolytic enzymes.

Swollen and Hydropic Oligodendrocytes and Axonal Degeneration

Myelinating glia play a fundamental role in promoting the maturation of the axon cytoskeleton, regulating axon trafficking parameters, and imposing architectural rearrangements such as the nodes of Ranvier and their associated molecular domains. In the setting of demyelination, these changes may be reversed or persist as maladaptive features, leading to axon degeneration (Pan and Chan, 2017) [105]. Most oligodendrocytes showed remarkable hydropic changes, characterized mainly by lacunar enlargement of smooth (Golgi complex) and rough endoplasmic reticulum and nuclear envelope. A process of disassembly of nuclear pore complex was frequently observed, although some nuclear pore complexes remained unaltered. The nuclear envelope appeared irregularly dilated and followed a contoured trajectory. Some oedematous oligodendrocytes also exhibited necrotic cytoplasmic membranes [106-110]. The mitochondria appear with a swollen, clear matrix and without enlargement of the intracristae and double membrane spaces. Reactive oligodendrocytes invade the degenerated myelinated axons, the periaxonal space and emit pseudopodic expansions to phagocyte the axoplasm (Figures 14&15) [111-115].

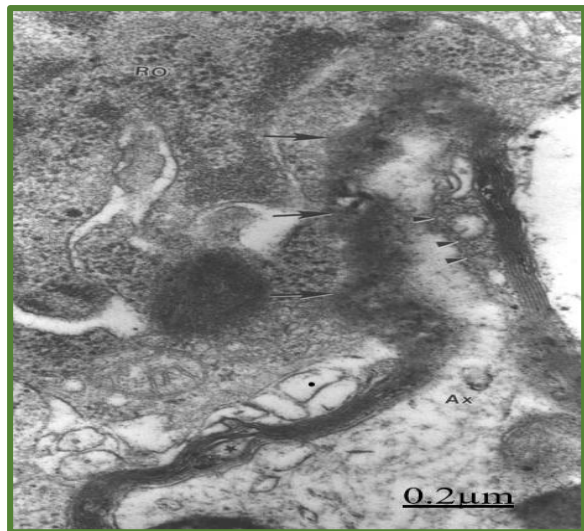

Figure 14: Brain trauma. Subdural hematoma. Reactive oligodendrocyte attached to a degenerated myelinated axon (arrows). The axoplasm (Ax) show the fragmented cytoskeletal structures. The arrowheads indicate the site of invading oligodendroglial phagocytosing pseudopods.

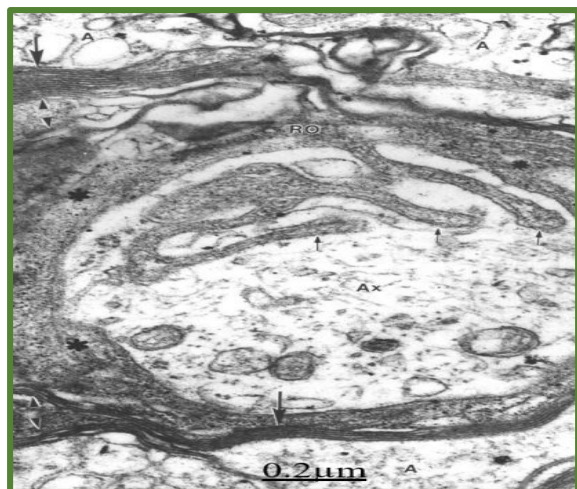


Figure 15: Brain trauma. Subdural hematoma. Reactive oligodendrocyte phagocytosing the axoplasm of a degenerated myelinated axon by means of pseudopodic expansions (short arrows). The long arrow indicates the vacuolated myelin sheath. The arrowheads point out the isolated myelin layers.

Phagocytosis by Dark Hypertrophic Astrocytes

In most cases examined, the degenerated axons are mainly phagocytosed by astrocytes, microglial cells, and non-nervous and invading professional phagocytes. The engulfed myelin fragments suffer stratifications, distortion, granular disintegration and a lytic process within the cytoplasm of phagocytic cells [116-120]. Sometimes the formation of myelin figures is also observed within the phagocytes. The myelin debris may appear within membranous compartments of phagocytic vacuoles or either free in the cytoplasmic matrix. Some astrocytes with phagocytic ability show numerous osmiophilic vesicles and myelinic residual bodies dispersed throughout the entire cytoplasm. Dark reactive astrocytes also phagocytose the degenerated myelinated axons (Figure 16) [121-126].

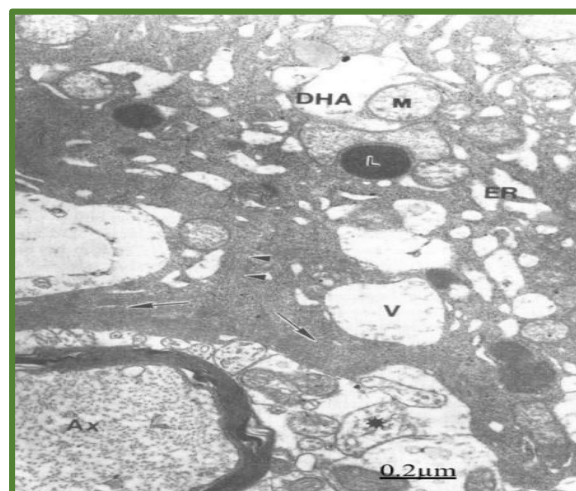


Figure 16: Brain trauma. Subdural hematoma. Dark hypertrophic astrocyte (DHA) phagocytosing a degenerated myelinated axon (Ax). This phagocytic astrocyte exhibits dark enlarged endoplasmic reticulum (ER) and large vacuoles (V), dark lysosomes (L), and long pseudopods (arrows). Invading monocytes from inflammatory reaction also participate in digestion and clearance of degenerated myelinated axons (Figure 17).

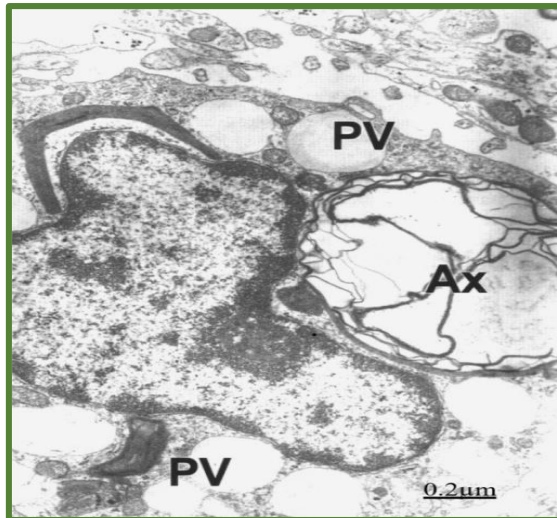


Figure 17: Brain trauma. Sudural hematoma. Invading monocyte from the inflammatory reaction displaying phagocytic vacuoles (PV) and a phagocytosed myelinated axon (Ax).

Concluding Remarks

In traumatic brain injuries of human edematous cerebral cortex degenerated myelinated axons in the gray matter underwent varicose fiber swelling, clear and dark types of axonal degeneration, myelin sheath vacuolization and distortion, formation of myelin ovoids, invagination and retraction of axoplasm, rupture of axolemma, cytoskeletal disruption featured by increased or reduced number of neurofilaments and fragmentation of microtubules, retraction of axoplasm, enlargement of periaxonal space, and partial or total disappearance of axoplasmic organelles. Phagocytosis of degenerated myelinated axons by reactive oligodendrocytes, astrocytes, microglial cells, and non-nervous professional phagocytes is observed in mild and severe traumatic brain edema.

References

1. Terry RD, Harkin JC (1959) Wallerian degeneration and regeneration of peripheral nerve. In: The Biology of Myelin. Korey S.A.(Ed.), P.B. Hoeber, New York 303-320.
2. Webster H de F (1962) Transient focal accumulation of axonal mitochondria during the early stages of Wallerian degeneration. J. Cell Biol 12: 361-377.
3. Lee JC (1963) Electron microscopy of Wallerian degeneration. /. Comp. Neurol 120: 65-71.
4. Nathaniel EJH, Pease DC (1963) Degenerative changes in rat dorsal roots during Wallerian degeneration. /. Ultrastruct. Res 9: 511-532.
5. Colonnier M (1964) Experimental degeneration in the cerebral cortex. J. Anat 98: 47-54.
6. Lee JC, Bakay L (1965) Ultrastructural changes in the edematous central nervous system. I. Triethyltin edema. Arch. Neurol 13: 48-57.
7. Singer M, Steinberg MC (1972) Wallerian degeneration: a reevaluation based on transected and colchicine-poisoned nerves in the amphibian triturus. Am. J. Anat 133: 51-84.
8. Cook RD, Wisniewsky HMJ (1973) The role of oligodendroglia in Wallerian degeneration of the optic nerve. Brain Res 61: 191-206.
9. Cook RD, Ghetti B, Wisniewsky HM (1975) The pattern of Wallerian degeneration in the optic nerve of newborn kittens: an ultrastructural study. Brain Res 75: 261-275.
10. Lubinska L (1977) Early course of Wallerian degeneration in myelinated fibers of the rat phrenic nerve. Brain Res 130: 47-63.
11. Tani E (1964) Electron microscope study on Wallerian degeneration of optic nerve. J. Neuropathol. Exp. Neurol 23: 62-65.
12. Jacobsen A (1967) An electron microscopic study of Wallerian degeneration in the pyramidal tract. Neurology 17: 298.
13. Lampert PW (1968) Fine structural changes of myelin sheaths in the central nervous system. In The structure and function of nervous tissue. Bourne G. (Ed.), Academic Press, New York I: 187-203.
14. Bignami A, Ralston HJ (1969) The cellular reaction to Wallerian degeneration in the central nervous system of the cat. Brain Res 13: 444-461.
15. Dunkerley GB, Duncan D (1969) A light and electron microscopic study of the normal and the degenerating corticospinal tract in the rat. J. Comp. Neurol, 137: 155-184.
16. Gray EG, Hamlyn LH (1972) Electron microscopy of experimental degeneration in the avian optic tectum. J. Anat. (London) 96: 309-316.
17. Hirano A (1972) The pathology of the central myelinated axon. In The structure and function of nervous tissue. Bourne G. ed., Academic Press, New York V: 73-156.

18. Fernando DA (1973) An electron microscopic study of the neuroglial reaction in Wallerian degeneration of the corticospinal tract. *Acta Anat* 86: 459-473.
19. Aldskogius H (1974) Indirect Wallerian degeneration in intramedullary root fibers of the kitten hypoglossal nerve. Light and electron microscopical observations on silver impregnated section. *Neurobiology* 4: 132-150.
20. Balentine J (1977) Complex oligodendroglial invaginations within myelinated nerve fibers of the central nervous system during axonal degeneration. *J. Neuropathol. Exp. Neurol* 36: 897-906.
21. Lampert PW, Schochet SS (1968) Demyelination and re-myelination in lead neuropathy. Electron microscopic studies. *J. Neuropathol. Exp. Neurol* 27: 527-545.
22. Sluga E (1967) Observations on the white matter in human brain edema. In: *Brain Edema*. Klatzo L., & Seitelberger, F. (Eds.), Springer-Verlag, New York 223-239.
23. Schlaepfer WW (1974) Calcium-induced degeneration of axoplasm in isolated segments of rat peripheral nerve. *Brain Res* 69: 203-215.
24. Tucek S, Hanzlikova V, Stranikova D (1978) Effect of ischemia on axonal transport of choline acetyltransferase and acetylcholinesterase and on ultrastructural changes of isolated segments of rabbit nerves *in situ*. *J. Neurol. Sci* 36: 237-246.
25. Erb DE, Povlishock JT (1988) Axonal damage in severe traumatic brain injury: an experimental study in cat. *Acta Neuropathol* 76: 347-358.
26. Blumberg PC, Jones NR, North JB (1989) Diffuse axonal injury in head trauma. *J. Neurol. Neurosurg. Psychiatry*, 52: 838-841.
27. Shigemori M, Kikuchi N, Tokutomi T, Ochiai S, Kuramoto S (1992) Coexisting diffuse axonal injury (DAI) and outcome of severe head injury. *Acta Neurochir* 55: 37-39.
28. Yamaki T, Murakami N, Iwamoto Y, Nakagawa Y, Ueda S, et al. (1992) Pathological study of diffuse axonal injury patients who died shortly after impact. *Acta Neurochir* 119: 153-158.
29. Gennarelli TA (1993) Mechanisms of brain injury. *J. Emerg. Med* 1: 5-11.
30. Povlishock JT (1993) Pathobiology of traumatically induced axonal injury in animals and man. *Ann. Emerg. Med* 22: 980-986.
31. Povlishock JT, Kontos HA (1992) The role of oxygen radicals in the pathobiology of traumatic brain injury. *Hum Cell* 5: 345-353.
32. Christman CW, Grady MS, Walker SA, Holloway KL, Povlishock JT (1992) Ultrastructural studies of diffuse axonal injury in humans. *J. Neurotrauma* 11: 173-186.
33. Pettus EH, Christman CW, Giebel ML, Povlishock JT (1994) Traumatically induced altered membrane permeability: its relationship to traumatically induced reactive axonal change. *J. Neurotrauma* 11: 507-522.
34. Povlishock JT, Buki A, Koizumi H, Stone J, Okonkwo DO (1999) Initiation mechanisms involved in the pathobiology of traumatically induced axonal injury and interventions targeted at blunting their progression. *Acta Neurochir* 73: 15-20.
35. Hayes RL, Yang K, Whitson JS, Postmantur R (1995) Cytoskeletal derangements following central nervous system injury: modulation by neurotrophic gene transfection. *J. Neurotrauma* 12: 933-941.
36. Pierce JE, Trojanowski JQ, Graham DI, Smith DH, McIntosh TK. (1996) Immunochemical characterization of alterations in the distribution of amyloid precursor proteins and beta amyloid peptide after experimental brain injury in the rat. *Journal of Neuroscience* 16: 1083-1090.
37. Posmantur RM, Kampfl A, Liu SJ, Heck K, Taft WC, et al. (1996a) Cytoskeletal derangements of cortical neuronal processes three hours after traumatic brain injury in rats: an immunofluorescence study. *J. Neuropathol. Exper. Neurol* 55: 68-80.
38. Posmantur RM, Kampfl A, Taft WC, Bhattacharjee J, Dixon CE, et al. (1996b) Diminished microtubule-associated protein 2 (MAP2) immunoreactivity following cortical impact brain injury. *J. Neurotrauma* 13: 125-137.
39. Saatman KE, Graham DI, McIntosh TK (1998) The neuronal cytoskeleton is at risk after mild and moderate brain injury. *J. Neurotrauma* 15: 1047-1058.
40. Povlishock JT, Christman CW (1995) The pathobiology of traumatically induced axonal injury in animals and humans: a review of current thoughts. *J. Neurotrauma* 12: 555-564.
41. Povlishock JT, Christman CW (1996) The pathobiology of traumatically induced axonal injury in animals and humans: A review of current thoughts. In *Traumatic Brain Injury Bioscience and Mechanics*. Bandak F.A., Eppinger, R.H., & Ommaya A.K., (Eds.), Mary Ann Liebert Inc. Pub., New York 51-59.

42. Povlishock JT, Pettus EH (1996) Traumatically induced axonal damage: evidence for enduring changes in axolemmal permeability with associated cytoskeletal change. *Acta Neurochir* 66: 81-86.
43. Maxwell W.(1996) Histopathological changes at central nodes of Ranvier after stretch-injury. *Microsc. Res. Tech* 34: 522-535.
44. Fitzpatrick MO, Maxwell WL, Graham DI (1998) The role of the axolemma in the initiation of traumatically induced axonal injury. *J. Neurol. Neurosurg. Psychiat* 64 : 285-287.
45. Bramlett HM, Kraydieh S, Geen EJ, Dietrich WD (1997) Temporal and regional patterns of axonal damage following traumatic injury: a beta amyloid precursor protein immunocytochemical study in rats. *J. Neuropathol. Exper. Neurol* 56: 1132-1141.
46. Wang H, Duan G, Zhang J, Zhou D (1998) Clinical studies on diffuse axonal injury in patients with severe closed head injury. *Chin. Med. J* 111: 59-62.
47. Wang JY, Hou L (2000) Model of diffuse axonal injury and focal brain injury in rats. *Hunan Yi Ke Da Xue Xue Bao* 28: 233-237.
48. Nashmi R, Fehlings MG (2001) Changes in axonal physiology and morphology after chronic compressive injury of rat thoracic spinal cord. *Neuroscience* 104: 235-251.
49. Raghupathi R, Margulies SS (2002) Traumatic axonal injury after closed head injury in the neonatal pig. *J. Neurotrauma* 19: 843-853.
50. Gorries C, Oakes S, Duflou J, Blumbergs P, Waite PM (2002) Axonal injury in children after motor vehicle crashes: extent, distribution and size of axonal swelling using beta -APP immunohistochemistry. *J. Neurotrauma* 19: 1171-1182.
51. Maxwell WL, Domleo A, Mc Coll G, Jafari SS, Graham DI (2003) Post-acute alterations in the axonal cytoskeleton after traumatic axonal injury. *J. Neurotrauma* 20: 151-168.
52. Saatman KE, Abai B, Grosvenor A, Vorwerk CK, Smith DH, et al. (2003) Traumatic axonal injury results in biphasic calpain activation and retrograde transport impairment in mice. *J. Cerebr. Blood Flow Metab* 23: 34-42.
53. Hamberger A, Huang YL, Zhu H, Bao F, Ding M, et al. (2003) Redistribution of neurofilaments and accumulation of beta amyloid protein after brain injury by rotational acceleration of the head. *J. Neurotrauma* 20: 169-178.
54. Smith DH, Chen XH, Iwata A, Graham DI (2003) Amyloid beta accumulation in axons after traumatic brain injury in humans. *J. Neurosurg* 98: 1072-1077.
55. Hoshino S, Kobayashi S, Furukawa T, Asakura T, Teramoto A (2003) Multiple immunostaining methods to detect traumatic axonal injury in the rat fluid-percussion injury model. *Neurol Med Chir* 43: 165-173.
56. Stone JR, Okonkwo DO, Dialo AO, Rubin DG, Mutlu LK, et al. (2004) Impaired axoplasmic transport and altered axolemmal permeability occur in distinct populations of damaged axons following traumatic brain injury. *Exper. Neurol* 190: 59-69.
57. Hall ED, Detloff MR, Johnson K, Kupina NC (2004) Peroxynitrite-mediated protein nitration and lipid peroxidation in a mouse model of traumatic brain injury. *Journal of Neurotrauma* 21: 9-20.
58. Khan AA (2004) Wallerian degeneration in the optic nerve of the rabbit. *Cell Tissue Organs* 177: 104-109.
59. Rodriguez-Paez AC, Brunschwig JP, Bramlett HM (2005) Light and electron microscopic assessment of progressive atrophy following moderate traumatic brain injury in the rat. *Acta Neuropathol. (Berl)* 109: 603-616.
60. Stys PK (2005) General mechanisms of axonal damage and its prevention. *J. Neurol. Sci* 233: 3-13.
61. Chung RS, Staal JA, McCormach GH, Dickson TC, Cozen MA, et al. (2005) Mild axonal stretch injury in vitro induces a progressive series of neurofilaments alterations ultimately leading to delayed axotomy. *J. Neurotrauma* 22: 1081-1091.
62. Marmorou CR, Walker SA, Davis CL, Povlishock JT (2005) Quantitative analysis of the relationship between intraaxonal neurofilament compaction and impaired axonal transport following diffuse traumatic brain injury. *J. Neurotrauma* 22: 1066-1080.
63. Reeves TM, Phillips LL, Povlishock JT (2005) Myelinated and unmyelinated axons of the corpus callosum differ in vulnerability and functional recovery following traumatic brain injury. *Exp. Neurol* 196: 126-137.
64. Gallyas G, Pal Farkas O, Docsi T (2006) The fate of axons subjected to traumatic ultrastructural neurofilament compaction: an electron microscopic study. *J. Neuropathol. Exper. Neurol* 111: 229-237.

65. Kelley BJ, Farkas O, Lifshitz J, Povlishock JT (2006) Traumatic axonal injury in the perisomatic domain triggers ultrarapid Secondary axotomy and Wallerian degeneration. *Exper. Neurol* 198: 350-360.
66. Petzold A, Rejdak K, Belli A, Sen J, Keir G, et al. (2005) Axonal pathology in subarachnoid and intracerebral hemorrhage. *J. Neurotrauma* 22: 407-414.
67. Petzold A, Keir G, Kay A, Kerr M, Thompson EJ (2006) Axonal damage and outcome in subarachnoid haemorrhage. *J. Neurol. Neurosurg. Psychiatr* 77: 753-759.
68. Gruner JE (1967) Electron microscopic observation on human brain edema studied in biopsy material. In: Brain edema. Klatzo I. & Seitelberger F. (Eds.), Springer-Verlag, New York 202-206.
69. Zulch KJ (1967) Neuropathological aspects and histological criteria of brain edema and brain swelling. In: Brain Edema. Klatzo I. and Seitelberger F. (Eds.), Springer-Verlag, New York 95-116.
70. Hirano A, Dembitzer H (1969) The transverse bands as a means of access to the periaxonal space of the central myelinated nerve fiber. *J. Ultrastruct. Res* 28: 141-149.
71. Bakay L, Lee CJ (1965) Pathophysiology of human brain edema. In: Cerebral edema. Thomas Ch. (Ed.), Springfield 69-79.
72. Lampert PW, Schochet SS (1968a) Electron microscopic observations on experimental spongy degeneration of the cerebellar whitematter. *J. Neuropathol. Exp. Neurol* 27: 210-220.
73. Blakemore WF, Palmer AC, Noel PBR (1972) Ultrastructural changes in isoniazid-induced brain edema in the dog. *J. Neurocytol* 1: 263-378.
74. Adams CWM, Leibowitz S (1969) Pathology of demyelinating diseases. In: "The structure and function of nervous tissue". Bourne G. (Ed.), Academic Press, New York Ill: 310-381.
75. Watson JD (1974) La importancia de las interacciones quimicas debiles. *Biologia Molecular del Gen. Fondo Educativo Interamericano. S.A.USA* 95-129.
76. Finean SB, Woolf AL (1962) An electron microscope study of degenerative changes in human cutaneous nerve. *J. Neuropathol. Exp. Neurol* 21: 105-115.
77. Povlishock JT (1992) Traumatically induced axonal injury: pathogenesis and pathobiological implications. *Brain Pathol* 2: 1-12.
78. Pettus EH, Povlishock JT (1996) Characterization of a distinct set of intra-axonal ultrastructural changes associated with traumatically induced alteration in axolemmal permeability. *Brain Research* 722: 1-11.
79. King CE, Canty AJ, Vickers JC (2001) Alterations in neurofilaments associated with reactive brain changes and axonal sprouting following physical injury to the rat neocortex. *Neuropathol. Applied Neurobiol* 27: 115-126.
80. Stone JR, Singleton RH, Povlishock JT (2001) Intra-axonal neurofilament compaction does not evoke local axonal swelling in all traumatically injured axons. *Exp. Neurol* 172: 320-331.
81. Lampert PW (1967) A comparative microscopic study of reactive, degenerating, regenerating and dystrophic axons. *J. Neuropathol. Exp. Neurol* 26: 345-367.
82. Huh JW, Raghupati R, Laurer HL, Helfaer MA., Saatman KE (2003) Transient loss of microtubule associated protein 2 immunoreactivity after moderate brain injury in mice. *J. Neurotrauma* 20: 975-984.
83. Lampert PW, Kies MW (1967) Mechanism of demyelination in allergic encephalomyelitis of guinea pig. An electron microscopic study. *Exp. Neurol* 18: 210-223.
84. Bacstrom B, Collins VP (1987) Cytoskeletal changes in axons of rats exposed to 2,5 hexanedial, demonstrated using monoclonal antibodies. *Neurotoxicology* 8: 85-96.
85. Gennarelli TA, Thibault LE, Tipperman R, Tomei G, Sergot R, et al. (1989) Axonal injury in the optic nerve: a model simulating diffuse axonal injury in the brain. *J. Neurosurg* 71: 244-253.
86. Shapira Y, Yadid G, Cotev S, Shohami E (1989) Accumulation of calcium in the brain following head trauma. *Neurol. Res* 11: 69-172.
87. Evans PH (1993) Free radicals in brain metabolism and pathology. *Brit. Med. Bull* 49: 577-587.
88. Ginsberg MD, Watson BD, Busto R (1988) Peroxidative damage to cell membranes following cerebral ischemia. A cause of ischemic brain injury. *Neurochem. Pathol* 9: 171-173.
89. Siesjo BK, Agar CD, Bengtson F (1989) Free radicals and brain damage. *Cerebr. Brain Metab. Rev* 1: 165-171.
90. Wilberger J (1996) Molecular basis of head injury. In: The Molecular Basis of Neurosurgical

- Disease. Raffel C., & Hars G.R. (Eds.), Williamand Wilkins, Baltimore, USA 296-303.
91. Practico D, Reiss P, Tang LX, Sung S, Rokach J, et al. (2002) Local and systemic increase in lipid peroxidation after moderate traumatic brain injury. *J. Neurochem* 80: 894-898.
92. Cervos-Navarro J, Lafuente JV (1991) Traumatic brain injuries: Structural changes. *J. Neurol. Sci* 103: S3-S14.
93. Cajal SR (1928) Degeneration and regeneration of the nervous system. Oxford University Press, London II.
94. Lampert P, Cressman M (1966) Fine structural changes of myelin sheath after axonal degeneration in the spinal cord. *Am. J. Pathol* 49: 1139-1155.
95. Laatsch RH, Cowan WM (1967) Electron microscopic studies of the dentate gyms of the rat. II. Degeneration of commissural afferents. *J. Comp. Neurol* 130: 241-262.
96. Baumgarten HG, Bjorklund A, Holstein AF, Nobin A (1972) Chemical degeneration of indolamine axons in rat brain by 5,6-dihydroxytryptamine. An ultrastructural study. *Z. Zellforsch* 129: 256-271.
97. Hopwood D (1972) Theoretical and practical aspect of glutaraldehyde fixation. *Histochem* 4: 267-303.
98. Lampert PW, Schochet SS (1968a) Electron microscopic observations on experimental spongy degeneration of the cerebellar whitmatter. *J. Neuropathol. Exp. Neurol* 27: 210-220.
99. Smith DH, Urvu K, Saatman KE, Trojanowski JQ, McIntosh TK (2003) Protein accumulation in traumatic brain injury. *Neuromol. Med* 4: 59-72.
100. Wolman M (1968) Myelin structure, ultrastructure and degeneration. In *Pathology of the Nervous System*. Minckler J. (Ed.), McGraw-Hill, NewYork I: 758-766.
101. Schlaepfer WW (1969) Experimental lead neuropathy: a disease of the supporting cells in the peripheral nervous system. *J. Neuropathol. Exp. Neurol* 28: 401-418.
102. Alizadeh A, Dyck SM, Karimi-Abdolrezaee S (2015) Myelin damage and repair in pathologic CNS: challenges and prospects. *Front Mol Neurosci* 8: 35.
103. Flygt J, Djupsjö A, Lenne F, Marklund N (2013) Myelin loss and oligodendrocyte pathology in white matter tracts following traumatic brain injury in the rat. *Eur J Neurosci* 38: 2153-65.
104. Hill RA, Li AM, Grutzendler J (2018) Lifelong cortical myelin plasticity and age-related degeneration in the live mammalian brain. *Nat Neurosci* 21: 683-695.
105. Zindler E, Zipp F (2010) Neuronal injury in chronic CNS inflammation. *Best Pract. Res. Clin. Anaesthesiol* 24: 551-62.
106. Pan S, Chan JR (2017) Regulation and dysregulation of axon infrastructure by myelinating glia. *J Cell Biol* 216: 3903-3916.
107. Bondareff W, Sjostrand J (1969) Cytochemistry of synaptosomes. *Exp. Neurol* 24: 450-458.
108. Castejón OJ (1980) Electron microscopic study of capillary wall in human cerebral edema. *J. Neuropathol. Exp. Neurol* 39: 296-327.
109. Cervos-Navarro J, Lafuente JV (1991) Traumatic brain injuries: Structural changes. *J. Neurol. Sci* S3-S14.
110. Gonatas NK, Martin J, Evangelista I (1967) The osmophilic particles of astrocytes, viruses, lipid droplets or products of secretion?. *J. Neuropathol. Exp. Neurol* 26: 369-376.
111. Halpain S, Spencer K, Graber S (2005) Dynamics and pathology of dendritic spines. *Progress in Brain Research* 147: 29-37.
112. Hirano A, Dembitzer H, Becker N, Zimmerman H (1969) On distribution of peroxidase in the triethyltin-intoxicated rat brain. *J. Neuropathol. Exp. Neurol* 28: 507-511.
113. Hirano A (1969) The fine structure of brain in edema. In *The structure and function of nervous tissue*. Bourne G. ed., Academic Press, New York II: 69-135.
114. Homayoun P, Rodriguez De Turco EB, Parkins NE, Lance DC, Soblosky J, et al. (1997) Delayed phospholipids degradation in rat brain after traumatic brain injury. *J. Neurochem* 69: 199-205.
115. Hu BR, Janelidze S, Ginsberg MD, Busto R, Perez-Pinzon M, et al. (2001). Protein aggregation after focal brain ischemia and reperfusion. *Journal of Cerebr. Blood Flow Metab* 21: 865-875.
116. Kampf A, Franz G, Aichner F, Pfausier B, Haring HP, et al. (The persistent vegetative state after closed head injury: clinical and magnetic resonance imaging findings in 42 patients. *J. Neurosurg* 89: 895-896.
117. McMahan VJ (1967) Fine structure of synapses in the dorsal nucleus of the lateral geniculate

- body of normal and blinded rats. Z. Zellforsch. Mikrosk. Anat 76: 116-146.
- 118.** Morley P, Tauskela JS, Hakim AM (1999) Calcium Overload. In Cerebral Ischemia. Walz, W. (Ed.), New Jersey, Humana Press 69-104.
- 119.** Ozawa K, Seta K, Araki A, Handa H (1967) The effect of ischemia on mitochondrial metabolism. J. Biochem 61: 512-514.
- 120.** Quarles RH, Everly JL, Brady RO (1973) Evidence for the close association of a glycoprotein with myelin in rat brain. J. Neurochem 21: 1177-1191.
- 121.** Povlishock JT (1992) Ultrastructural studies of diffuse axonal injury in humans. J. Neurotrauma 11: 173-186
- 122.** Sun X, Tg W, Zheng L Ultrastructural observations of effect of moderate hypothermia on axonal damage in animal models of diffuse axonal injury. Chin. J. Traumatol 5: 355-360.
- 123.** Tani E, Evans JP (1965) Electron microscope studies of cerebral swelling. II. Alterations of myelinated fibers. Acta Neuropathol 4: 604-623.
- 124.** Tavazzi B, Signoretti S, Lazzarino G, Amorini Am, Delfini R, et al. Cerebral oxidative stress and depression of energy metabolism correlate with severity of diffuse brain injury in rats. Neurosurgery 56: 582-589.
- 125.** Vaughn JE, Pease DC (1970) Electron microscopic studies of Wallerian degeneration in rat optic nerves. II. Astrocytes, oligodendrocytes and adventitial cells. J. Comp. Neurol 140: 207-226.
- 126.** Vaughn JE, Skoff RP (1972) Neuroglia in experimentally altered central nervous system. In The Structure and Function of Nervous Tissue. Bourne G. (Ed.), Academic Press, New York V: 39-70.

*Copyright: ©2018 Castejón OJ *. This is an open-access article distributed under the terms of the Creative Commons Attribution License, which permit unrestricted use, distribution, and reproduction in any medium, provided the original author and source are credited.*